International study of video review of concussion in professional sports

Gavin A Davis,[1,2] Michael Makdissi,[1,3] Paul Bloomfield,[4] Patrick Clifton,[5] Ruben J Echemendia,[6] Éanna Cian Falvey,[7] Gordon Ward Fuller,[7] Gary Green,[8] Peter Rex Harcourt,[5] Thomas Hill,[9] Nathan McGuirk,[4] Willem Meeuwisse,[6] John W Orchard,[9] Martin Raftery,[7] Allen K Sills,[10] Gary S Solomon,[10,11] Alex Valadka,[8] Paul McCrory[1]

► Additional material is published online only. To view please visit the journal online (http://dx.doi.org/10.1136/bjsports-2018-099727).

[1]Florey Institute of Neuroscience and Mental Health, Melbourne, Victoria, Australia
[2]Neurosurgery Department, Cabrini and Austin Hospitals, Melbourne, Victoria, Australia
[3]La Trobe Sport and Exercise Medicine Research Centre, La Trobe University, Melbourne, Victoria, Australia
[4]National Rugby League, Sydney, New South Wales, Australia
[5]Australian Football League, Melbourne, Victoria, Australia
[6]National Hockey League, Philadelphia, Pennsylvania, USA
[7]World Rugby, Dublin, Ireland
[8]Major League Baseball, New York City, New York, USA
[9]Cricket Australia, Melbourne, Victoria, Australia
[10]National Football League, New York City, New York, USA
[11]Department of Neurosurgery, Vanderbilt University Medical Center, Nashville, Tennessee, USA

Correspondence to
Professor Gavin A Davis, Suite 53 - Neurosurgery, Cabrini Hospital, Malvern, VIC 3144, Australia; gavin.davis@me.com

Received 25 June 2018
Revised 29 August 2018
Accepted 30 August 2018

Check for updates

© Author(s) (or their employer(s)) 2018. No commercial re-use. See rights and permissions. Published by BMJ.

To cite: Davis GA, Makdissi M, Bloomfield P, *et al*. *Br J Sports Med* Epub ahead of print: [*please include* Day Month Year]. doi:10.1136/bjsports-2018-099727

ABSTRACT

Background Video review has become an important tool in professional sporting codes to help sideline identification and management of players with a potential concussion.

Aim To assess current practices related to video review of concussion in professional sports internationally, and compare protocols and diagnostic criteria used to identify and manage potential concussions.

Methods Current concussion management guidelines from professional national and international sporting codes were reviewed. Specific criteria and definitions of video signs associated with concussion were compared between codes. Rules and regulations adopted across the codes for processes around video review were also assessed.

Results Six sports with specific diagnostic criteria and definitions for signs of concussion identified on video review participated in this study (Australian football, American football, world rugby, cricket, rugby league and ice hockey). Video signs common to all sports include *lying motionless/loss of responsiveness* and *motor incoordination*. The video signs considered by the majority of sports as most predictive of a diagnosis of concussion include *motor incoordination, impact seizure, tonic posturing* and *lying motionless.* Regulatory requirements, sideline availability of video, medical expertise of video reviewers and use of spotters differ across sports and geographical boundaries. By and large, these differences reflect a pragmatic approach from each sport, with limited underlying research and development of the video review process in some instances.

Conclusions The use of video analysis in assisting medical staff with the diagnosis or identification of potential concussion is well established across different sports internationally. The diagnostic criteria used and the expertise of the video review personnel are not clearly established, and research efforts would benefit from a collaborative harmonisation across sporting codes.

What are the findings?

- ► Video review is used in many professional sports to assist in the sideline detection and management of possible concussion.
- ► The video signs considered by most sports as most predictive of a diagnosis of concussion include motor incoordination, impact seizure, tonic posturing and lying motionless.
- ► There appears to be agreement among professional sports that the presence of these signs on video review requires removal from the field of play. While a number of the sports recommend permanent removal from play, there is no universal consensus and further research is required for validation of these signs.

How might it impact on clinical practice in the future?

- ► Improvements in definitions and interpretation of video signs of concussion can assist sideline physicians in identifying possible concussions which may otherwise not be detected.
- ► Further research to identify possible video signs that mandate permanent removal from play on the day is required.

INTRODUCTION

Sport-related concussion (SRC) is common, with an incidence of up to 18 concussions per 1000 athlete hours in professional sports.[1 2] Yet, despite SRC being a common neurological injury, its diagnosis is often challenging for the clinician, especially on the sideline.[3] This task can be even more complex and difficult in professional and elite sports where the speed of the game is faster (possibly with a corresponding greater force of impact), play is often more congested and clinical decisions need to be made quickly. The definition of SRC is complex,[4] which is exacerbated by the absence of an objective and reliable biomarker for the diagnosis of concussion. As such, SRC remains a clinical diagnosis. Obvious signs such as loss of consciousness present in fewer than 10% of cases,[5] and the diagnosis of SRC is often not easily apparent, yet failing to make an accurate diagnosis can have significant short-term and long-term consequences for the athlete.[6]

Early signs of SRC may be brief and may resolve completely by the time the medical staff arrive to assess the player. In the past, video review of potential concussive incidents were not available to the team's medical staff on the sideline, although it was available to the public watching the game via broadcast feeds. When shown on slow-motion replay, often from multiple angles by the

Br J Sports Med: first published as 10.1136/bjsports-2018-099727 on 27 September 2018. Downloaded from http://bjsm.bmj.com/ on 7 October 2018 by guest. Protected by copyright.

broadcaster, brief early signs of concussion (such as staggers) are more easily observed by broadcast viewers and expose the medical staff for 'missing' a concussion. To assist the team physicians with assessing possible concussive injuries, many sporting bodies have introduced the use of video for real-time assessment, and for post-hoc analysis and review. Video review affords the viewer the opportunity to watch the incident from multiple angles, repeatedly, in slow motion and to assess biomechanical and clinical features of the incident.

Professional sporting codes around the world have introduced video assessment for SRC concurrently. By and large, sports have followed a pragmatic approach, dictated more by cost and availability of resources than being driven by empirical scientific research. Practically, sports have adopted different management strategies around the in-game video review process, including the availability of broadcast feed that can be controlled by the team medical staff, addition of concussion 'spotters', use of a video 'tent', which allows a distraction-free environment for viewing the video, etc. Consequently, the approach by various professional sporting organisations with regard to the role of video review in concussion assessment and management has been variable.[7–22]

There are a number of signs of SRC that may be observable on video. These range from signs that are highly suggestive of a diagnosis of SRC (such as impact seizures, tonic posturing and motor incoordination) and others that are less specific (such as 'loss of responsiveness', facial injury or 'slow to get up').[8] One of the current limitations of video review, however, is that observable signs have limited sensitivity and specificity when compared with a clinical diagnosis of SRC.[9 11 15 17] Some sports have adopted a conservative approach whereby the presence of signs highly suggestive of a SRC requires 'immediate and permanent removal from play', whereas in other sports, video signs are used to identify a potential SRC but further clinical assessment is required before the diagnosis is firmly established. Consequently, the interpretation of the video signs associated with SRC and the implications for management currently vary from sport to sport.

It is likely that clinical signs of a possible concussion, observable with video review, are common to all sports, although sport-specific signs may be possible. There are other differences between sports that may impact the utility of individual signs, including use of protective equipment, size of the sporting field, linear or 360° play, number of athletes in play, location of cameras, etc. For example, signs such as 'blank and vacant look' may be useful in some sports but may be difficult to ascertain in others where helmets obscure facial expression of the athlete. It is important to examine whether commonalities should exist across sports in essential elements of video review.

The objective of this study was to assess practices related to video review of concussion in professional sports internationally, and compare protocols and criteria used to identify and manage potential concussions, in order to help establish a common standard and improve the identification and management of SRC on game day.

METHODS

Senior medical advisers and chief medical officers from major international sporting codes, including Australian Football League (AFL), Cricket Australia (CA), Major League Baseball (MLB), NFL, NHL, National Rugby League (NRL) and World Rugby (WR) were purposively sampled and invited to participate in the study. As a census sample of major sporting codes, a sample size calculation was not necessary. Each sport completed a standardised questionnaire assessing the following topics, as they pertain to the use of video review for concussion assessment in their sport:

- The source of the video feed.
- Video signs that result in permanent removal from play.
- Video signs that result in removal from play for further assessment.
- Definitions of the video signs.
- Biomechanical criteria.
- Qualification/status of video reviewers.
- Use of spotters.
- Time limits and locations for video review.
- Equipment provided for video review.
- Education provided for video staff.
- Laws of the game and audit.

Questionnaire content was informed by a literature review of published studies evaluating video review in sport and developed in consultation with sports medicine experts. Questions included both close-ended and open-ended questions. The survey was presented in Microsoft Excel and circulated by email between November 2017 and December 2017. Reminders were sent if there was no response by 4 weeks. Respondents provided consent to use their data. As the data content of this study is available in the public domain and does not contain any patient data, approval of the research ethics committee was not required.

The data were extracted independently by two researchers (GD and MM) according to pre-defined data definitions and tabulated to determine which video signs are common to all sports, which are common to most sports and which are sport-specific. Disagreements were resolved by arbitration, with referral to a third researcher if required. A narrative synthesis was performed to assess the consistency of definitions used across the sports, and to identify which signs and definitions should be incorporated into a 'core' group of video signs, and which should be 'optional' or sport-specific.

RESULTS

Seven sports that were invited to participate responded to the study. MLB is yet to incorporate video review into its concussion management protocols, and therefore MLB was excluded from further data synthesis. So six sports were included in the final analysis.

The questionnaire was completed by medical personnel from each sport. All six sports are currently using live, in-game video review as part of their concussion protocols. Competition organised by three out of the six sporting bodies is played in a single country (AFL, CA and NRL in Australia), with one sporting body running competition across two countries (NHL – Canada and USA), one competition playing games across three countries (NFL – USA, Mexico and England) and one sporting body running competition across multiple countries (WR – with 102 member unions and 17 associate unions).

Personnel

In all sports, experienced doctors are responsible for reviewing the video footage. NFL and NHL use certified athletic trainers (ATC) to watch the video feed and identify any suspicious head injury events (ie, act as concussion 'spotters'). In the NFL, the ATC spotters typically relay the video and their commentary to the sideline medical staff who must also view the video. On occasion, the sideline staff will initiate the review process by contacting the ATC spotters and asking them to obtain the video of a certain play so that the injury mechanism may be further

Br J Sports Med: first published as 10.1136/bjsports-2018-099727 on 27 September 2018. Downloaded from http://bjsm.bmj.com/ on 7 October 2018 by guest. Protected by copyright.

explored. Similarly, the NHL uses ATC as the primary video spotters, following which team physicians review the video in the medical room. Additionally, the NHL uses off-ice officials who have been trained as spotters to view the game live within the arena from a vantage point where they can see the entire ice surface. WR also allows for other 'appropriately trained' healthcare professionals (eg, physiotherapist) to act as video spotters. Currently NRL has an informal arrangement where the video technician may also act as a spotter and are trialling further spotter roles both at the ground and at a central video bunker.

WR also has an independent match-day doctor who is involved in the process of video review and NFL has an unaffiliated neurotrauma consultant (UNC) involved in the process on each sideline (and will have a third UNC located in the booth with the ATC spotters starting in the 2018–19 season). CA uses a single doctor at matches, employing the team doctor for international matches and an independent match day doctor at domestic matches.

Video source

Broadcast vision is used exclusively in two sports: CA and NFL. NHL and AFL use the Hawk-Eye system,[23] which allows multiple camera views and the video clip can be manipulated (including rewinding, slow motion and enlarging the field of view). NRL had used a combination of broadcast footage and started using the Hawk-Eye system in 2018. WR uses a variety of video sources (including Hawk-Eye or equivalent systems; eg, EVS, MyPlayXPlay, VoGo)[24–26] or broadcast footage, with the video source being dictated by the tournament organisers.

Equipment and location

Four sports (AFL, NHL, NRL and WR) use a video monitor that can be manipulated by the viewer. AFL and NRL have the video equipment located exclusively on the sidelines without the provision of a specific distraction-free environment. NFL has a video booth above the field (press box), which provides a private viewing area for the ATC spotters, who are then connected via headphones to the sideline medical staff; a sideline video monitor is provided to medical staff, showing the same views used by the concussion spotters. It is a requirement of the NFL concussion protocol that the injury video review is a part of *every* concussion evaluation done either on the sideline or in the locker room.[27] The medical treatment room is used for video assessment in the NHL, thus providing a distraction-free environment. For CA, there is no standard or formal place set aside for the medical assessment of the video and it varies depending on the broadcast conditions. In WR, the video review occurs in a neutral area between the team sideline areas, as well as in the medical room.

Video signs of possible concussion

The video signs used for decisions for '*Permanent removal from play*', and for '*Requires removal and assessment*' are listed in figure 1. *Permanent removal from play* mandates that the athlete may not return to play that day, whereas *Removal and assessment* requires sideline medical evaluation to confirm the diagnosis and disposition of the athlete. The two video signs common to every sport are *Loss of consciousness/responsiveness/Lying motionless* and *motor incoordination*. The video signs common to most sports are *impact seizure*, *tonic posturing* and *no protective action*.

While most sports mandate permanent removal from same-game play based on some video signs, one sport does not mandate permanent removal based on video signs but does have a protocol on mandatory removal, a standardised assessment and physician clinical decision making regarding diagnosis.

Definitions of video signs

The definitions of each sign used by the different sports are presented in online supplementary table 1.

Protocol

No sport has a time limit for the video assessment. In WR the video review is used initially to identify any suspicious head-impact events. A second video review is then undertaken off-field to identify immediate removal criteria (criteria 1). If there are no criteria 1 signs evident on video, the player undergoes an off-field assessment. Similarly, in NFL, the concussion spotter can call a 'Medical time-out' and contact either the team medical staff and/or an on-field official (side judge) via the official-to-official communication system following head-impact events with signs of concussion, if the injury was not noted by the sideline medical staff and play would otherwise continue without a medical evaluation of the potentially injured player.

Biomechanical video criteria of concussion

Only three of the sports include a biomechanical video criterion of concussion. The definitions provided involve an impact or trauma to the head, neck or body (with force transmitted to the head).

Compliance

Four sports (AFL, NFL, NRL and WR) include video assessment in the laws of the game. In two sports, it is included as part of the concussion protocol, but there are no specific corresponding regulatory laws or rules. In AFL and NRL, the team can be fined by the sport governing body for not following concussion protocols, and in the NFL all concussion protocol violations are investigated jointly with the players union, and fines and other punishments may be imposed for violations. The NHL may fine individual clubs for violations of the concussion protocol. Similarly, in WR cases may be referred to the Tournament Disciplinary Committee.

All sports have an audit process for monitoring compliance with the video assessment and concussion protocols. The reviews are conducted by nominated independent trained medical professionals. Information is provided to concussion spotters and the team's medical staff where appropriate. Furthermore, WR game analysts review match footage post-game for any missed significant head-impact events, and similar review processes are included in NRL and AFL.

Education

NFL, NHL and WR have education modules for their team's medical staff regarding the use of video assessment. The NHL also has education modules for their central and in-area game spotters. AFL does not have specific education modules but run yearly meetings for their medical staff with review and discussion of cases from the season. NRL uses elite head injury/concussion protocols online module, which includes video assessment training. NFL conducts annual meetings for medical personnel as well. CA has an annual conference to educate medical officers on concussion management but does not have specific education modules on video assessment.

Br J Sports Med: first published as 10.1136/bjsports-2018-099727 on 27 September 2018. Downloaded from http://bjsm.bmj.com/ on 7 October 2018 by guest. Protected by copyright.

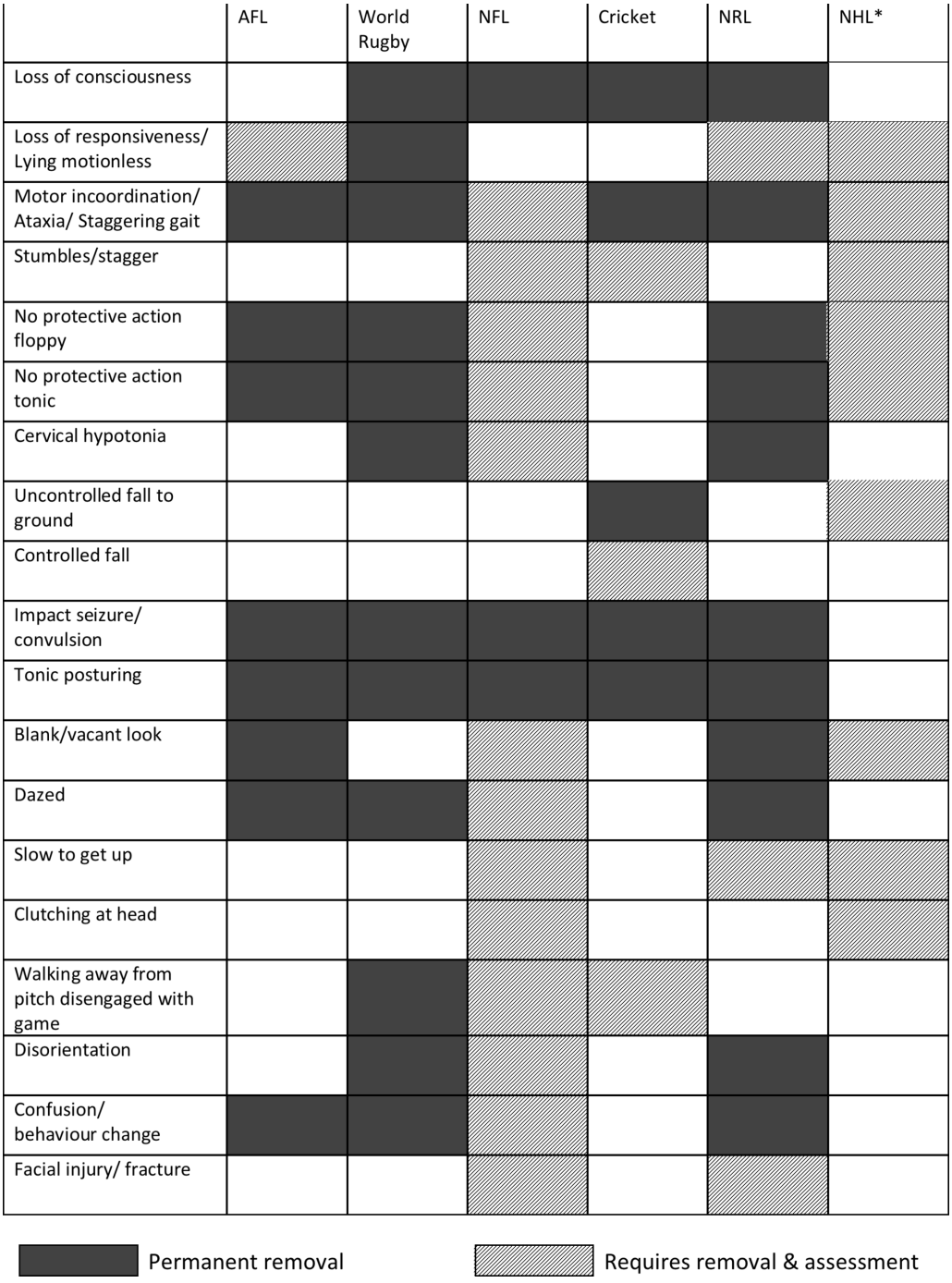

Figure 1 Video signs used in each sport. *Note*: In addition to above, removal and assessment in AFL if possible balance disturbance, tonic posturing or impact seizure; WR for any of the above if sign is possible/sub-threshold; NRL if possible motor incoordination, tonic posturing or impact seizure. *The NHL does not mandate permanent removal based on video alone, but has a protocol on mandatory removal, a standardised assessment and physician clinical decision making regarding diagnosis.

DISCUSSION

The use of video technology in concussion assessment in elite sports has evolved across different sports, in different continents, independent of each other. While there are numerous subtle differences in game-day practicalities, there are many similarities across the sports regarding the neurological criteria used.

Recent studies on the video signs associated with concussion have demonstrated good to fair inter-rater reliability on coding video signs of concussion. Similarly, the sensitivity and specificity of video signs were variable when compared with a clinical diagnosis of SRC.[9 11 15 17] Some of the limitations noted in these studies, however, included ambiguity in the early definitions and a reliance on broadcast view (which often failed to show a clear view of the player following impact).[9 11 15 17] In some cases, the broadcast views alone are insufficient as they cannot show all players on the field at all times, and thus, some injuries may be missed.

The current study highlights the differences in the approach to video assessment that have evolved in several major national and international sports. While there are many similarities in the

Br J Sports Med: first published as 10.1136/bjsports-2018-099727 on 27 September 2018. Downloaded from http://bjsm.bmj.com/ on 7 October 2018 by guest. Protected by copyright.

definitions and processes introduced by the sports to identify a possible concussion, there may be significant benefit in developing a common standard to help improve the identification and management of SRC on game day.

Video signs of concussion

Loss of consciousness or responsiveness, Lying motionless and *Motor incoordination* are video signs common to all sports. While there are some subtle differences in definitions used across the sports, each sport is referring to a similar neurological entity. It is evident that most sports use the term *Loss of consciousness,* however, assessment of conscious state requires direct clinical examination by a health practitioner (as occurs in the assessment of the Glasgow Coma Scale), and cannot be solely determined from video. *Loss of consciousness* and *Loss of responsiveness* are therefore best used as clinical signs, and the preferred term in assessing video signs of concussion is *Lying motionless*. The strict definition of *Lying motionless,* particularly regarding duration of motionless, has not been adequately examined and requires further investigation.

Motor incoordination is a video sign common to all sports, yet two-thirds of the sports recommend permanent same-game removal from play, and the other sports require removal and assessment when this video sign is present. There are some subtle definitional and terminology differences across the sports, with terms such as 'ataxia', 'staggering gait', 'loss of balance', 'stumbles' and 'clumsiness' all referring to the same entity, namely motor incoordination. Terms that incorporate gait in their nomenclature can be misleading, because often the motor incoordination is observed in the athlete on their hands and knees, attempting to rise from the ground or field, and before they commence with gait. Therefore, definitions and terms that only assess gait will miss the common entity of motor incoordination in an athlete not in the action of running/walking/skating. Although motor incoordination may be due to other pathology (eg, injury to the vestibular apparatus and lower limb injury), this is difficult to establish with clinical certainty on the sidelines. Until such time that a direct, objective sideline diagnostic test of concussion is established, it is recommended that sports adopt a conservative approach. Consequently, it is recommended that, in the absence of a definitive alternate cause (eg, lower limb musculoskeletal injury), an athlete with definite motor incoordination following head trauma should be considered to have a concussion and permanently removed from play, or in ice-based sports with skates, subjected to a mandatory comprehensive off-ice evaluation.

Impact seizure and tonic posturing are included in the criteria for all sports, except in NHL. Impact seizures following head trauma are uncommon,[28] but tonic posturing has been demonstrated to be common in sports such as Australian football.[22] Tonic posturing is often brief and can be difficult to identify. It is possible that the use of medical personnel to assess video, in some sports, experienced in the assessment of seizures and neurological diseases, heightens clinician awareness of these signs and clinical experience affords sufficient confidence to interpret these signs on video. Conversely, in sports using personnel with less neurological experience, it is possible that there is less confidence in identifying these signs on video, or, if such personnel are unfamiliar with these signs, they will not look for them, and thus not include them in their results. Alternatively, it is possible that there are significant sport-specific differences in the occurrence or frequency of impact seizure or tonic posturing. Whether the use of helmets or other body protection equipment in some sports modifies the appearance of such signs is not yet clear and requires further investigation.

The video sign of *No protective action*, *Uncontrolled fall to the ground* and *Cervical hypotonia* are phrases that describe the same phenomenon where by the player does not use any protective manoeuvres as they fall to the ground, implying that they have already lost consciousness.[8] In a detailed reliability study on video signs in AFL, it was noted that players could be 'floppy' or 'stiff' as they fell to the ground and failed to protect themselves.[8] It is acknowledged that *No protective action – Stiff* is actually the presence of tonic posturing that occurs on impact, before the athlete lands on the ground, and it is therefore not surprising that there is a strong correlation between sports that incorporate these two video signs into their protocols. The video sign *No protective action – Floppy* is identical to the 'ragdoll' sign, often described by video assessors; however, it is preferable to use the more descriptive terms, rather than the term ragdoll, because it is less ambiguous and allows for clear differentiation between those who fall while flaccid (floppy) and tonic (stiff). Two sports use the additional term *cervical hypotonia* when assessing video for *No protective action*. In some circumstances a player with *No protective action – Floppy* may have the arms held in a tackle such that the flaccid characteristic is only identified superior to the cervico-thoracic junction. Some refer to this as cervical hypotonia; however, this term may be misleading as it may suggest that the hypotonia is restricted to the cervical region only. There may be merit in sub-categorising *No protective action – Floppy*, as *Arms-free* or *Arms-held*, to clarify the terminology in this group.

Blank and vacant look is a sign that, when present, is highly correlated with the diagnosis of concussion.[8] However, it is a sign that can be difficult to assess with video, because it requires an un-obstructed video view of the athlete's face and eyes and can be obscured by the presence of helmets and face shields. Further, familiarity with the individual athlete is important, because of the variability in athletes' normal appearance, and as such, a team doctor's familiarity with the athlete is at an advantage in identifying this video sign.

Disorientation and *Confusion/behaviour change* are used by a few sports; however, these signs are best elicited during the neurological examination. These signs can be inferred, to a degree, by odd athlete behaviour, such as running in the wrong direction on the field, but disorientation, from a neurocognitive perspective, requires formal clinical examination and cannot be determined from video alone.

The video signs of *Slow to get up* and *Clutching at head* are used by several sports for removal and assessment, but no sport incorporates these signs into criteria for permanent same-game removal from play. They may be useful markers that an event has occurred and warrants further medical attention, but are non-specific for the diagnosis of concussion. The video sign *Facial injury/Suspected facial fracture* is also not sufficiently specific to the diagnosis of concussion, and no sport incorporates it into the criteria for permanent same-game removal from play.

It is apparent that there are very few differences in the definitions used by the different sporting bodies, and it is likely that, while each sport developed their processes independently, clinicians advising sporting bodies on protocols would have appraised themselves of the published literature at the time, and therefore there was some degree of acceptance of published definitions, where it was considered that the definitions were appropriate for that sport, and could not be improved upon. Some definitions are different across the sporting spectrum, and this is most

Br J Sports Med: first published as 10.1136/bjsports-2018-099727 on 27 September 2018. Downloaded from http://bjsm.bmj.com/ on 7 October 2018 by guest. Protected by copyright.

likely due to difficulties in creating video analogies for neurological bedside clinical examination findings. For example, *Loss of consciousness/responsiveness* is variably defined as 'prolonged immobility >5 s not reacting to external environment', or 'a player lies motionless on the ice' or 'lying on ground (>1 s) does not appear to move or react, respond or reply appropriately to the game situation'.

Technology and personnel

The professional sports organisations involved in this study find the use of video review by medical staff to be an important and useful component of SRC assessment. Such video should be made available to medical staff whenever possible. Ideally however, the video review system should accommodate viewing from multiple camera angles, with facility for playback at varying speeds. This allows sideline medical personnel the opportunity to visualise the impact and subsequent signs, which may only be visible on limited camera angle views. Whether or not additional support from a video technician is required depends on the ease of use of the system employed, and experience and comfort level of the medical staff in the use of the system.

A number of sports provide a distraction-free/private viewing area in which the video assessment can be undertaken. It is unclear whether this results in any significant difference in the reviewers' performance in the identification of video signs of concussion.

NFL and NHL use ATC as video spotters, who themselves don't make a diagnosis of concussion, but inform the team's medical staff when a potential concussive event has been observed. With the required number of game-day tasks being performed by medical staff, and multiple other distractions associated with caring for team personnel on the sideline, the addition of other observers to help identify potential concussions is useful.

NFL (two ATC for each game) and NHL (ATC or physical therapist) use video spotters in addition to sideline medical staff to facilitate identification of head injury events. The NHL also has in-area spotters who watch games live (not on video) to identify visible signs not adequately captured on video. Currently NRL has an informal arrangement where the video technician may also act as a spotter. In WR coaches and the team's medical staff are encouraged to report suspicious video signs to the independent match day doctor (MDD) for further assessment. In the AFL, while there is no formal match day spotter, the video technician is used as an informal spotter used for post-match compliance assessment by AFL medical officials. The other sports do not incorporate non-medical-spotters into their game-day regulations.

While this use of video spotters is incorporated into some sports, in most sports an experienced team and/or independent doctor is responsible for reviewing the video, and, in all sports it is ultimately the responsibility of the doctor to make the diagnosis of concussion. The reliability of experienced medical staff, rather than non-medical personnel, in identifying the video signs across many sports needs to be established, as does the reliability of the video signs, either in isolation or as a combination, in predicting a diagnosis of concussion.

LIMITATIONS

This study examines the use of video technology in the game-day assessment of concussion in six professional sports as of 2018. Most of these sports are played in Australia and North America, with one sport (WR) played across 119 nations (however, not all 119 nations have ready access to video technology). The majority of sporting participants are professional males. These results are not necessarily generalisable across all sports and may not be applicable to non-professional athletes, in addition to women, adolescents, children or non-contact sports.

The confirmation of a diagnosis of concussion is a clinical decision, and in the absence of a validated biomarker of concussion, there is no doubt that video studies of concussion are at risk of type one error (false-positive, in which the video suggests signs of concussion, but a concussion has not occurred), and type two error (false-negative, in which there are no videos signs of concussion, but clinically concussion is confirmed). Given the absence of a valid biomarker, and the potential for further injury if a concussed individual is not removed from play, it is preferable to err on the side of caution and accept a higher incidence of type one error.

RECOMMENDATIONS

1. All contact/collision professional sporting codes should provide broadcast video to side-line medical personnel, in real time, preferably with access to multiple camera angles, and facility for playback at variable speeds.
2. There appears to be agreement among professional contact sports that the presence of *Lying motionless, Tonic posturing, Impact seizure or Motor incoordination* on video review requires removal from the field of play. While many professional sporting bodies recommend permanent removal from play, there is not universal consensus, and further research is required for validation of these signs in professional collision/contact sports.
3. Other aspects that require validation and/or discussion in a future concussion consensus meeting include:
   i. The applicability of other/additional video signs across all sporting codes as either general or sport-specific visible signs.
   ii. Whether any signs should rise to the level of mandating 'no return to play on the day'.
   iii. The utility of specific biomechanical signs.
   iv. The level of education and training required for personnel to review video for presence of signs of concussion.

Contributors GAD and MM contributed to the conception of the work. All authors contributed to the acquisition, analysis or interpretation of data, drafting the work or revising it critically for important intellectual content, final approval of the version published and agreement to be accountable for all aspects of the work.

Funding No funding was provided for this study.

Competing interests GAD is an Honorary member of the AFL Concussion Working Group. MM is an Honorary member of the AFL Concussion Working Group. PB is Chief Medical Officer of NRL. PC is Head of Health, Safety & Laws, AFL. RJE is Co-Chair, NHL NHLPA Concussion Subcommittee and Chair of the MLS Concussion Committee. ECF is Member of World Rugby concussion working group. GWF is a member of the World Rugby Concussion Working Group. GG is Medical Director, Major League Baseball. PRH is AFL Medical Director. TH is State Medical Officer, Cricket Australia. NM is General Manager, Competitions and Operations, Football, NRL. WM is Medical Director, National Hockey League. JO is Chief Medical Officer, Cricket Australia. MR is Chief Medical Officer, World Rugby. AKS is Chief Medical Officer, NFL. GSS is Senior Adviser, NFL Department of Health and Safety. AV is Consultant for Mild Traumatic Brain Injury, Major League Baseball. PM is an Honorary member of the AFL Concussion Working Group. ICJME disclosure forms have been provided.

Patient consent Not required.

Provenance and peer review Not commissioned; internally peer reviewed.

REFERENCES

1 Gibbs N, Watsford M. Concussion incidence and recurrence in professional Australian Football match-play: a 14-year analysis. *J Sports Med* 2017;2017:1–7.

Br J Sports Med: first published as 10.1136/bjsports-2018-099727 on 27 September 2018. Downloaded from http://bjsm.bmj.com/ on 7 October 2018 by guest. Protected by copyright.

2 Nathanson JT, Connolly JG, Yuk F, *et al*. Concussion Incidence in Professional Football: Position-Specific Analysis With Use of a Novel Metric. *Orthop J Sports Med* 2016;4.
3 Patricios J, Fuller GW, Ellenbogen R, *et al*. What are the critical elements of sideline screening that can be used to establish the diagnosis of concussion? A systematic review. *Br J Sports Med* 2017. doi: 10.1136/bjsports-2016-097441. [Epub ahead of print 7 Mar 2017].
4 McCrory P, Feddermann-Demont N, Dvořák J, *et al*. What is the definition of sports-related concussion: a systematic review. *Br J Sports Med* 2017;51:877–87.
5 Guskiewicz KM, Weaver NL, Padua DA, *et al*. Epidemiology of concussion in collegiate and high school football players. *Am J Sports Med* 2000;28:643–50.
6 McCrory P, Meeuwisse W, Dvořák J, *et al*. Consensus statement on concussion in sport-the 5th international conference on concussion in sport held in Berlin, October 2016. *Br J Sports Med* 2017;51:838–47.
7 Davis G, Makdissi M. Use of video to facilitate sideline concussion diagnosis and management decision-making. *J Sci Med Sport* 2016;19:898–902.
8 Makdissi M, Davis G. The reliability and validity of video analysis for the assessment of the clinical signs of concussion in Australian football. *J Sci Med Sport* 2016;19:859–63.
9 Makdissi M, Davis G. Using video analysis for concussion surveillance in Australian football. *J Sci Med Sport* 2016;19:958–63.
10 Fuller CW, Fuller GW, Kemp SP, *et al*. Evaluation of World Rugby's concussion management process: results from Rugby World Cup 2015. *Br J Sports Med* 2017;51:64–9.
11 Fuller GW, Kemp SP, Raftery M. The accuracy and reproducibility of video assessment in the pitch-side management of concussion in elite rugby. *J Sci Med Sport* 2017;20:246–9.
12 Tucker R, Raftery M, Kemp S, *et al*. Risk factors for head injury events in professional rugby union: a video analysis of 464 head injury events to inform proposed injury prevention strategies. *Br J Sports Med* 2017;51:1152–7.
13 Cross MJ, Tucker R, Raftery M, *et al*. Tackling concussion in professional rugby union: a case-control study of tackle-based risk factors and recommendations for primary prevention. *Br J Sports Med* 2017. doi: 10.1136/bjsports-2017-097912. [Epub ahead of print 13 Oct 2017].
14 Bruce JM, Echemendia RJ, Meeuwisse W, *et al*. Development of a risk prediction model among professional hockey players with visible signs of concussion. *Br J Sports Med* 2018;52.
15 Echemendia RJ, Bruce JM, Meeuwisse W, *et al*. Can visible signs predict concussion diagnosis in the National Hockey League? *Br J Sports Med* 2018;52.
16 Hutchison MG, Comper P, Meeuwisse WH, *et al*. A systematic video analysis of National Hockey League (NHL) concussions, part I: who, when, where and what? *Br J Sports Med* 2015;49:547–51.
17 Gardner AJ, Howell DR, Levi CR, *et al*. Evidence of concussion signs in national rugby league match play: a video review and validation study. *Sports Med Open* 2017;3:29.
18 Gardner AJ, Iverson GL, Quinn TN, *et al*. A preliminary video analysis of concussion in the National Rugby League. *Brain Inj* 2015;4:1182–5.
19 Gardner AJ, Iverson GL, Stanwell P, *et al*. A video analysis of use of the new 'Concussion Interchange Rule' in the National Rugby League. *Int J Sports Med* 2016;37:267–73.
20 Gardner AJ, Levi CR, Iverson GL. Observational review and analysis of concussion: a method for conducting a standardized video analysis of concussion in rugby league. *Sports Med Open* 2017;3:26.
21 Gardner AJ, Wojtowicz M, Terry DP, *et al*. Video and clinical screening of national rugby league players suspected of sustaining concussion. *Brain Inj* 2017;31:1918–24.
22 McCrory PR, Berkovic SF. Video analysis of acute motor and convulsive manifestations in sport-related concussion. *Neurology* 2000;54:1488–91.
23 Hawk-Eye. Home of world athletics. www.hawkeyeinnovations.com (accessed 28 May 2018).
24 EVS. About EVS. www.evs.com/en (accessed 28 May 2018).
25 Play MPX. A new WordPress site. http://www.streamsportsav.com (accessed 28 May 2018).
26 Vogosport. Offer an innovative in-venue Live & Replay experience. http://www.vogosport.com/en/ (accessed 28 May 2018).
27 Ellenbogen RG, Batjer H, Cardenas J, *et al*. National football league head, neck and spine committee's concussion diagnosis and management protocol: 2017-18 season. *Br J Sports Med* 2018;52:894–902.
28 Kuhl NO, Yengo-Kahn AM, Burnette H, *et al*. Sport-related concussive convulsions: a systematic review. *Phys Sportsmed* 2018;46:1–7.

Br J Sports Med: first published as 10.1136/bjsports-2018-099727 on 27 September 2018. Downloaded from http://bjsm.bmj.com/ on 7 October 2018 by guest. Protected by copyright.